Compression for the Treatment of Epidermal Pigmented Lesions with the 595-nm Pulsed Dye Laser

JEROME M. GARDEN, MD,*† ABNOEAL D. BAKUS, PHD,† AND YACOV DOMANKEVITZ, PHD‡

BACKGROUND The 595-nm pulsed dye laser has been the standard of care for many vascular lesions and has rarely been used in the treatment of epidermal pigmented lesions.

OBJECTIVE The objective was to investigate the effectiveness and safety of a compression technique for the treatment of epidermal pigmented lesion using a modified 595-nm pulsed dye laser with no epidermal cooling.

METHODS Twelve subjects (mean age 58 years) underwent treatments using a modified 595-nm dye laser with a compression handpiece and no epidermal cooling. Treatments were performed with radiant exposures of 7 to 12 J/cm^2, 7-mm spot size, and 1.5-ms pulse duration. Each subject received one to four treatments, 4 to 6 weeks apart. Follow-up evaluations were held before each treatment and 4 months after last treatment.

RESULTS Clearance of 75% to 100% was obtained in 43, 59, 76, and 79% of the lesions treated after one, two, three, and four treatments respectively. The fourth treatment was evaluated 4 months posttreatment. Side effects included immediate erythema and edema and rare cases of transient hyperpigmentation and atrophy. No purpura and long-lasting side effects were observed.

CONCLUSION The compression technique with a modified 595-nm pulsed dye laser system is effective and safe for the treatment of epidermal pigmented lesions.

Equipment and funding for this study were provided by Candela Corp. Yacov Domankevitz is a full-time employee of Candela. A patent application has been submitted for the compression handpiece described in this article.

Lasers and light source technology are becoming increasingly popular modalities for nonablative treatment of skin. Minimal or no healing time is required, thus reducing patient inconvenience. Also, significant reduction in associated risk makes this approach attractive to both physician and patient.[1–4] The treatment of epidermal pigmented lesions such as solar lentigines, ephelids, and seborrheic keratosis is a major component in nonablative skin treatment. Patients many times consider these lesions to be cosmetically undesirable and seek treatment for removal.

The 595-nm pulsed dye laser has been the standard of care for many vascular lesions because of strong hemoglobin absorption (Figure 1). Although the 595-nm wavelength is also well absorbed by melanin (Figure 1), consistent clearance of pigmented lesions has not been frequently seen. This is due in part to the desired therapeutic approach of many times applying a low level of radiant exposure to minimize postprocedural purpura. The energies used in such an approach would be too low to effectively treat pigmented lesions. In addition, even in those cases where purpura formation is induced with higher energies, the epidermal cooling commonly used during these procedures also decreases the interaction between laser energy with the superficial pigmented lesion.

Tanghetti and colleagues[5] performed the first evaluation on the effects of 595- and 585-nm pulsed dye

*Departments of Dermatology and †Biomedical Engineering, Northwestern University, Chicago, Illinois; ‡Candela Corporation, Wayland, Massachusetts

ISSN: 1076-0512 • Dermatol Surg 2007;34:1–5 • DOI: 10.1111/j.1524-4725.2007.34035.x

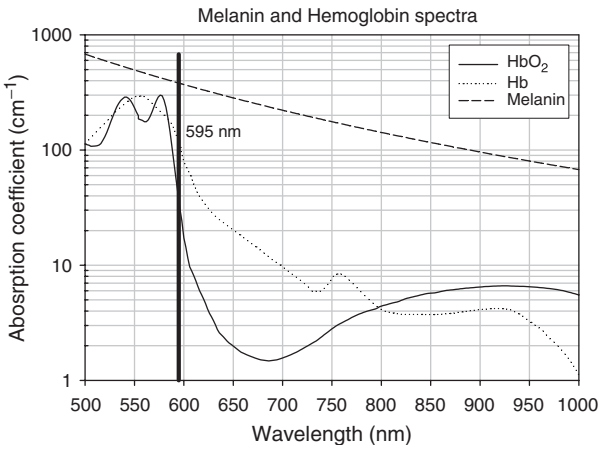

Figure 1. Absorption spectra of blood and melanin in the range of 500 to 1,000 nm.

lasers on reduction of superficial dyspigmentation. They used subpurpuric radiant exposures ranging from 3 to 4 J/cm^2, a spot size of 10 mm, and fixed pulse duration of 0.5 ms.[5] They reported minimal to modest improvements in clearing pigmented lesions.

Kono and coworkers[6] used the 595-nm pulsed dye laser for the treatment of facial lentigines in Asian patients. They showed that the pulsed dye laser was capable of facial lentigo therapy in the Asian patient by attaching a flat glass to the laser's handpiece and compressing against the skin.

Recently in a pilot study, Kauvar and coworkers,[7] treating both vascular and pigmented lesions in photodamaged patients with the pulsed dye laser and a compression handpiece, showed responsiveness in both vascular and pigment lesions being similar to each other. The objective of this study was to prospectively evaluate the effectiveness and safety of a compression technique with modification of both a compression element and a 595-nm pulsed dye laser without epidermal cooling, for the treatment of epidermal pigmented lesions.

Methods

Twelve Caucasian female subjects with epidermal pigmented lesions consisting of lentigines and flat seborrheic keratoses, ages ranging from 39 to 75 years (mean age 58 years), participated in this study. Subjects were enrolled under institutional review board approval and full informed consent was signed by each patient. The study protocol conformed to the guidelines of the 1975 Declaration of Helsinki. Eleven subjects had Fitzpatrick skin type I to III and one subject had skin type IV. Exclusion criteria included subjects with past scarring or current infection in the treatment area, suntan, or known photosensitivity or with a history of poor healing or keloid formation.

The subjects were treated with a modified 595-nm pulsed dye laser (Candela Corp., Wayland, MA) with a compression handpiece. This laser emits its energy during each pulse in up to eight subpulses depending on the overall pulse duration. This is in distinction of earlier 595-nm pulsed dye laser (Vbeam, Candela Corp.) generating up to only four subpulses and resulting in greater peak power and energy per subpulse. At 1.5-ms pulse duration, there are four subpulses per pulse generated by the modified laser system relative to three subpulses per pulse in past pulsed dye lasers (Vbeam).

Treatments were performed with radiant exposure of 7 to 12 J/cm^2 with the majority at 9 to 10 J/cm^2, a 7-mm spot size, and a fixed 1.5-ms pulse duration. All lesions in an entire area up to 2 by 2 in. on the back of the hand, chest, back, and face were treated.

A fused-silica meniscus optical element was used to compress the skin (Figure 2). During treatment, the convex surface of the meniscus optical element was pressed firmly against the skin to a point where the skin blanched. The treatment end point was darkening of the lesion. No topical or oral anesthetics were used.

Each subject received one to four treatments, 4 to 6 weeks apart depending on subject response to the treatment. Posttreatment evaluations were conducted before a subsequent procedure and at 4 months after last treatment. Macrophotographic images

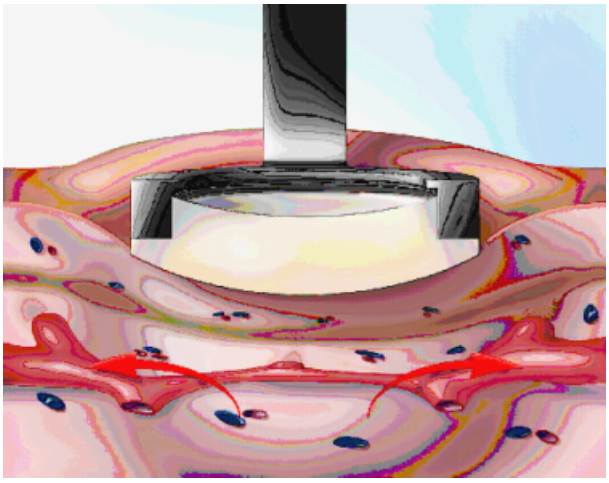

Figure 2. Meniscus compression element. The convex side is pressed firmly on the skin and displaces the blood away from the irradiated field.

were taken before each treatment and at every follow-up visit using a digital camera (Fuji S2 Pro, Fuji USA, Valhalla, NY) with a 60-mm microlens (Nikkor, Nikon Corp., Tokyo, Japan). A clinical evaluation for adverse effects was performed and recorded immediately posttreatment and at subsequent follow-up visits. Clearance was assessed by evaluation by a blinded observer of pre-treatment photographs and direct posttreatment evaluation.

Results

The procedures were well tolerated by all subjects with subjects describing only mild procedural discomfort. Ninety-four percent of all lesions were treated with radiant exposures of 9 to 10 J/cm^2. From all lesions treated, 43, 59, 76, and 79% had 75% to 100% clearance after one, two, three, and four treatments, respectively. The fourth treatment was evaluated at the 4-months follow-up visit (Figures 3 and 4).

Side effects included immediate erythema and edema in all cases and rare cases of transient hyperpigmentation and atrophy. No purpura was observed with the compression handpiece. Ninety-two percent of these side effects occurred after the first treatment. No side effects were observed by the investigator when the patients were examined at the 4-months

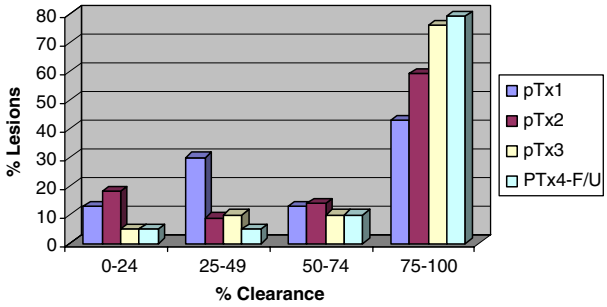

Figure 3. Percent clearance of the pigmented lesions. From all lesion treated, 43, 59, 76, and 79% had 75% to 100% clearance after one, two, and three treatments and 4 months after a fourth treatment follow-up, respectively.

follow-ups, and no subjects complained of any adverse effect at any of the follow-up visits.

Discussion

The 595-nm pulsed dye laser has not been commonly used for the treatment of epidermal pigmented

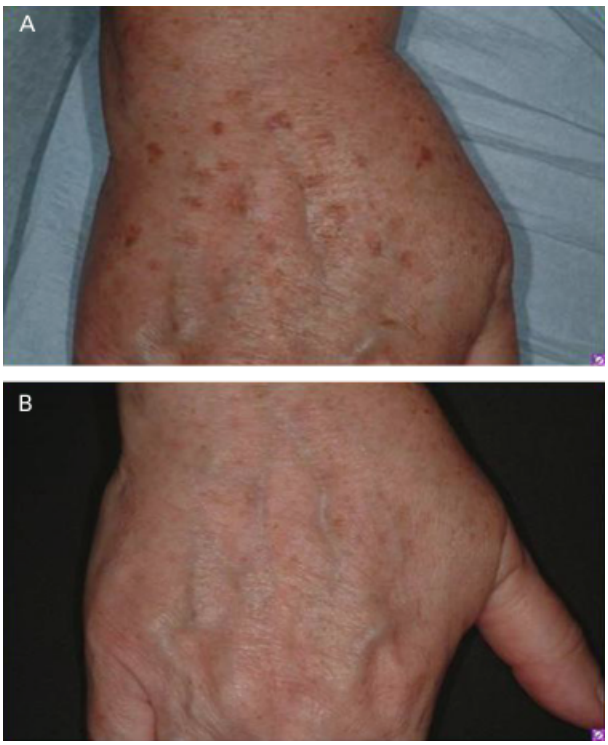

Figures 4. (A) Before and (B) after photographs of epidermal pigmented lesions treated once with the compression technique using a radiant exposure of 9 J/cm^2, pulse duration of 1.5 ms, and spot size of 7 mm.

lesions even though this wavelength is well absorbed by melanin. The main reason is due to the desire to reduce purpura. Many vascular directed procedures are performed with subpurpuric radiant exposures, which are not energetic enough for the treatment of epidermal pigmented lesions. The purpura threshold at 595 nm without compression at 2-ms pulse duration was found to be 7.1 J/cm^2.[8] In this study, we discovered that when using the compression technique, an effective radiant exposure range for treating epidermal pigmented lesions was from 9 to 10 J/cm^2 for 1.5-ms pulse duration. This combination of pulse duration and radiant exposure would easily have produced undesired purpura without compression and in this study with compression there was no observed purpura. In addition, epidermal cooling frequently used during procedures to protect the epidermis would cool down the targeted epidermal lesion sufficiently to necessitate increasing radiant exposures greater than what may be desired to effectively treat epidermal pigmented lesions. With increasing energies would come a greater potential of undesired side effects.

Kono and coworkers[6] used a compression technique with the 595-nm pulsed dye laser, for the treatment of facial lentigines in Asian patients. By compressing a transparent flat optical element against the skin, the blood in the superficial vessels was squeezed out and displaced from the irradiated zone, thus minimizing absorption by blood in the superficial vessels and allowing the use of shorter pulses while reducing purpura and unwanted side effects.

We used in this study a convex surface compression optical element (Figure 2). Convex surface allows for a more uniform blood displacement from the irradiated field, when pressed against the skin. A flat optical element can exert greater force around its periphery, and as a result, blood can pool in various regions of the flat surface.

We have chosen to obtain the convex compression surface from a meniscus lens with a zero optical power and not a planoconvex optical element. A planoconvex optical element with the desired radius of curvature produces a converging beam. When contact between skin and the optical element is not maintained, an accidental skin exposure to a focused laser could occur, resulting in an unwanted damage to the skin. Having a nonconverging beam from a meniscus lens greatly limits this problem.

We used a pulse duration of 1.5 ms because it closely matches the thermal relaxation of the pigment target within the epidermal layer.[6] Following the principles of selective photothermolysis helps confine the zone of thermal damage to the desired target and to minimize unnecessary adverse effects and pain.[9] Using shorter laser pulses such as produced by Q-switched lasers tend to work through photomechanical effects rather than photothermal and have higher probability of inducing mechanical damages that often lead to purpura and postinflammatory pigmentary changes. It has been suggested that longer pulse durations light sources are more desirable for the treatment of epidermal pigmented lesions than very short ones because the risk of adverse effects such as postinflammatory hyperpigmentation is significantly reduced.[6,10] Also, the currently used pulsed dye laser has smaller peak power and energy subpulses than previously used system which may reduce any contributory mechanically induced damage.

Kauvar and coworkers[7] using both a modified pulsed dye laser and a compression handpiece for the treatment of photodamaged changes of erythema, telangiectasia, and pigmented lesions reported similar response of both vascular and pigmented lesions at 26% to 50% improvement. Their study treated entire anatomic regions up to three treatments and included various pigmented lesions.

Kono and coworkers[6] have demonstrated after a single treatment an 83.3% degree of clearing when treating only facial lentigines. We achieved similar degree of clearance with up to four treatments. Lesions from various anatomic regions were treated including back, chest, upper/lower extremities, and face. We also treated a wide range of lesions

including dark and light lenitigines and flat seborrheic keratoses. Seborrheic keratoses and lighter lentigines were more resistant to therapy. It is likely that the amount of delivered procedures and percentage of more resistant lesions in the study group will dictate ultimate therapeutic outcome.

In conclusion, the study demonstrated that the compression technique with a modified compression element and 595-nm pulsed dye laser system is effective and safe for the treatment of epidermal pigmented lesions. Finally, sufficient compression to achieve adequate extravasation of underlying blood filled vessels is mandatory to minimize or eliminate postprocedural pupura. Darker lentigines appear to be most responsive.

Acknowledgement We express our appreciation to Kenneth Malomo for his contributions to this study, which included data retrieval, entry, and analysis.

References

1. Sadick NS. Update on non-ablative light therapy for rejuvenation: a review. Lasers Surg Med 2003;32:120–8.
2. Alam M, Hsu TS, Dover JS, et al. Nonablative laser and light treatments: histology and tissue effects-a review. Lasers Surg Med 2003;33:30–9.
3. Tanzi EL, Lupton JR, Alster TS. Lasers in dermatology: four decades of progress. J Am Acad Dermatol 2003;49:1–31.
4. Kilmer SL, Garden JM. Laser treatment of pigmented lesions and tattoos. Semin Cutan Med Surg 2000;19:232–44.
5. Tanghetti E, Sherr EA, Alvarado SL. Multipass treatment of photodamage using the pulse dye laser. Dermatol Surg 2003;29:686–90.
6. Kono T, Manstein D, Chan HH, et al. Q-switched ruby versus long-pulsed dye laser delivered with compression for treatment of facial lentigines in Asians. Lasers Surg Med 2006;38:94–7.
7. Kauvar NB, Rosen N, Khrom T. A newly modified 595-nm pulsed dye laser with compression handpiece for the treatment of photodamaged skin. Lasers Surg Med 2006;38:808–13.
8. Tanghetti E, Sierra RA, Sherr EA, Mirkov M. Evaluation of pulse-duration on purpuric threshold using extended pulse pulsed dye laser. Lasers Surg Med 2002;31:363–6.
9. Anderson RR, Parish JA. Selective photothermolysis: precise microsurgery by selective absorption of pulsed radiation. Science 1983;220:524–7.
10. Chan HH. The use of lasers and intense pulsed light sources for the treatment of acquired pigmentary lesions in Asians. J Cosmet Laser Ther 2003;5:198–200.

Address correspondence and reprint requests to: Jerome M. Garden, MD, 150 E. Huron Street, Suite 1200, Chicago, IL 60611-2946, or e-mail: j-garden@northwestern.edu