

Vbeam™ pulsed dye Laser Treatment of Facial Rosacea

Jeffrey S. Dover, M.D., F.R.C.P.C.

Director, SkinCare Physicians, Chestnut Hill, Massachusetts, USA

Murad Alam, M.D.

Surgery Fellow, SkinCare Physicians, Chestnut Hill, Massachusetts, USA

Introduction

Rosacea is a chronic inflammatory cutaneous disorder that occurs in about 13 million Americans.^{1,2} Onset typically occurs between ages 30 and 50 in fair-skinned people of northern and eastern European origin. Early rosacea manifests as diffuse background erythema and flushing. In later stages, the vascular component is more prominent, with the development of telangiectasia on the nose, nasolabial folds, cheeks, glabella, and chin. Acneiform papules and pustules can emerge in the same distribution. More common in women, rosacea may be more severe in men, in whom large inflammatory nodules and soft-tissue hypertrophy may be disfiguring. Ocular rosacea, including erythema and telangiectasia, is seen in over half of rosacea patients.

The pathogenesis of rosacea is not understood. Recent reviews have repudiated the postulated association with *Helicobacter pylori* infection. *Demodex folliculorum* has also not been conclusively shown to be causative.

Rosacea is treatable but not curable.³ Common rosacea triggers, such as sun,

stress, hot weather, hot drinks, alcohol, and spicy foods, should be avoided by susceptible patients. Acneiform papules are typically improved by topical metronidazole, and nonresponders to this may benefit from topical clindamycin, other topical antibiotics, or sulfacetamide lotion. Topical corticosteroids must be applied cautiously, since long-term use can worsen telangiectasia and induce atrophy. Long-term oral antibiotic administration may be necessary to control papulopustules.

Surface vascularity in rosacea is minimally improved by medications. pulsed dye laser treatment remains the gold standard for treatment of redness, telangiectasia, and transient flushing. Historically, while patients were pleased with the final results of pulsed dye laser, they were reluctant to receive this intervention because of the inevitability of one to two weeks of post-treatment purpura.^{4,5} Difficult to conceal even with makeup, the dark purple color was embarrassing to patients in social and professional settings.

New pulsed dye lasers, such as the Vbeam, offer the possibility of treating



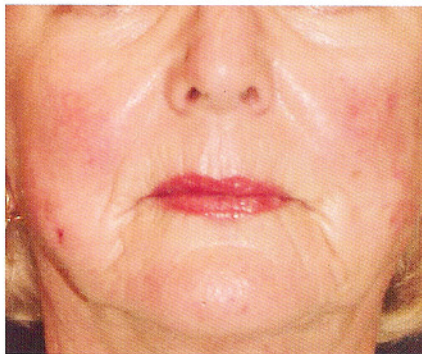Jeffrey S. Dover, M.D.,
F.R.C.P.C.



Murad Alam, M.D.

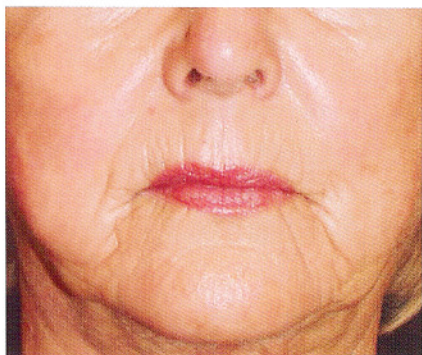


Figure 1



Pre-treatment

Figure 2



After three treatments
at six-week intervals

rosacea with longer pulse durations, thus minimizing the post-operative purpura without diminishing the quality of the therapeutic results.

Method

A purpura-free treatment is most effective for patients with diffuse redness or pinkness but no large, individually visible blood vessels. Very fine, discrete telangiectasia also respond well to purpura-free treatment.

After signing an informed consent for pulsed dye laser treatment, patients were treated with the Vbeam at the highest fluence possible without inducing purpura. In most cases, this required the 10 ms pulse duration, the 10 mm spot size, and fluences ranging from 6 to 7.5 J/cm². The redder the face, the lower the threshold for purpura, and hence the fluence.

The entire involved area was treated during each laser session. The number of pulses depended on the total area. On average, each patient received three treatments at six-week intervals.

Results

There was a greater than 80% improvement seen in all 25 patients treated. See Figures 1 and 2.

There was no post-operative purpura at the settings used. There were no side

effects noted in any of these patients. Posttreatment trace redness and edema were noticeable in some patients and always resolved within a few hours.

Discussion

The pulsed dye laser benefits from a long history (15+ years) of safety and success in the treatment of vascular lesions. An abundance of articles in the dermatology and plastic surgery literature corroborates the wide range of potential applications.⁶

The most recent pulsed dye lasers maintain the effectiveness of the older technology and add the possibility of purpura-free treatment. While the purpura may speed the clearance of certain lesions, and seems to remain necessary for removal of more dense vascular anomalies like port wine stains, purpura-free treatment of rosacea is a wonderful option for patients.

In conclusion, longer pulsed dye lasers, such as the Vbeam, provide physicians with a dramatic new tool, which is purpura-free treatment of rosacea for some patients. For these individuals, who previously avoided laser therapy, the Vbeam can be life altering.

Bibliography

1. Millikan L. Recognizing rosacea. *Postgrad Med* 1999;105(2):149-158.
2. Hirsch RJ, Weinberg JM. Rosacea 2000. *Cutis* 2000;66:125-128.
3. Thiboutot DM. Acne and rosacea: New and emerging therapies. *Dermatol Clin* 2000;18:63-71.
4. Ross M, Watcher MA, Goodman MM. Comparison of the flashlamp pulsed dye laser with the argon tunable dye laser with robotized handpiece for facial telangiectasia. *Lasers Med Surg* 1993;13:374-378.
5. Broska P, Martinho E, Goodman MM. Comparison of the argon tunable dye laser with the flashlamp pulsed dye laser in the treatment of facial telangiectasia. *J Dermatol Surg Oncol* 1994;20:749-753.
6. Richards KA, Garden JM. The pulsed dye laser for cutaneous vascular and nonvascular lesions. *Semin Cutan Med Surg* 2000;19:276-286.



530 Boston Post Road
Wayland, MA 01778
Phone: 508-358-7637
Fax: 508-358-5569

Vbeam is a trademark of Candela Corporation.
To find out more about Candela and its products, contact your authorized Candela representative, or call 1-800-733-8550 in the USA. Outside the USA contact the office nearest you or visit our website at <http://www.clzr.com>. 0920-23-0065 Rev. 01 6/01