Ablative Fractionated CO_2 Laser Resurfacing for the Neck: Prospective Study and Review of the Literature

Emily P. Tierney MD and C. William Hanke MD MPH
Laser and Skin Surgery Center of Indiana, Carmel, IN

ABSTRACT

Background: Ablative laser resurfacing of the neck has been tested with the ultrapulsed CO2, ablative Er:YAG and short pulse duration CO2 laser with mixed results in terms of efficacy and side effect profiles. Given the preliminary reports of safety and efficacy of ablative fractional photothermolysis (AFP) for the face, we set out to assess the efficacy of AFP for the neck.
Design: A prospective pilot study for neck resurfacing in 10 subjects with a series of one-to-three treatment sessions. Treatment sessions were administered at six-to-eight week intervals with blinded physician photographic analysis of improvement at two months post-treatment. Blinded physician photographic evaluation was performed of four clinical indicators, skin texture, skin laxity, rhytides and overall cosmetic outcome.
Results: The number of treatments required for improvement of neck texture and laxity ranged from 1–3, with an average of 1.4. For skin texture, the mean score improved 62.9% (95% CI: 57.4%, 68.4%), skin laxity, 57.0% (53.2%, 60.8%), and rhytides, 51.4% (48.3%, 54.5%). For overall cosmetic outcome, the mean score improved 59.3% (55.1%, 63.5%) at two months post treatment.
Conclusion: In this prospective study, AFP was both safe and effective for the treatment of neck laxity, rhytids and skin texture. The degree of improvement observed in wrinkling, texture and laxity after AFP coupled with the benign side effect profile has not been reported with previous trials of ablative laser resurfacing of the neck.

INTRODUCTION

Resurfacing of facial skin for the improvement of rhytides, scars, lentigines and textural changes associated with photoaging has been developed and refined throughout the last two decades.[1] Initially, dermabrasion was the treatment of choice,[9] followed by superficial to medium depth chemical peels and most recently, laser resurfacing.[1] However, consistently throughout the evolution of laser resurfacing, the unpredictability and potential adverse effects for resurfacing on non-facial skin was appreciated.[2]

Ablative laser resurfacing of the neck has been tested with the ultrapulsed CO_2, ablative Er:YAG and short pulse duration CO_2 laser with mixed results in terms of efficacy and side effect profiles. One of the most promising reports of this technology was by Behroozan et al.[1] in 1999 with the short pulse duration ablative CO_2 laser without a scanner (90μsec pulse duration, 3-mm spot size, 500-mJ pulse energy treated without a scanner for two passes), where a series of 308 patients treated demonstrated a mean 39% improvement in neck tightening.

Other reports of efficacy for neck resurfacing with standard ablative CO_2 and Er:YAG devices have demonstrated variable efficacy and incidence of adverse effects. In a case series by Fitzpatrick RE and Goldman MP,[2] after treatment of 10 patients with an ultrapulsed CO_2 laser (at the same settings used for facial resurfacing), three out of 10 patients developed hypertrophic scarring and four out of 10 patients developed permanent hypopigmentation. Kilmer et al[3] reported that the use of the ultrapulsed CO_2 laser was safer when one pass was utilized at a very low energy and density setting with a computer pattern generator. The authors noted greater improvements in blending the skin color of both the face and neck, when the two areas were treated together. However, ultrapulsed CO_2 laser resurfacing of the neck resulted in minimal improvements in skin texture. In terms of side effect profile, in the series of 100 patients reported treated with these conservative parameters, there were 12 cases of temporary post-inflammatory hyperpigmentation, one case of delayed onset permanent hypopigmentation and no incidence of scarring.

Jimenez and Spencer[4] reported a series of patients treated with the ablative Er:YAG laser resurfacing off the face, including the hands, arms and neck. The authors reported significant complications of post-operative infections, hyperpigmentation and prolonged wound healing. In addition, the improvement observed after Er:YAG resurfacing was modest, where three out of five patients had 0–25% improvement, one had 25–50% improvement and one had 50–75% improvement. There are some small case series documenting improvement with the Er:YAG laser with a more benign side effect profile. Goldberg and Meine[5] reported a series of 10 patients with neck rhytides treated with the ablative Er:YAG laser, where all patients showed fair to excellent results with no scarring or pigmentary changes

at six months. Goldman MP et al.[6] reported a case series in 20 patients treated with the ablative Er:YAG laser, with a mean improvement in skin color of 37% and for skin texture, 39%.

The difference between resurfacing facial and neck skin is theorized to result from the decreased density of pilosebaceous units on the neck relative to the face.[1,7–10] Wound healing following resurfacing procedures is thought to proceed from the pilosebaceous units.[1,7–10] This decreased density of pilosebaceous units is thought to both delay re-epithelialization and prolong wound healing as well as to increase the risk of scarring.[1,7–10] Others have attributed the complications of scarring and pigmentation on the neck to the thinner nature of the dermis, which is on average 140μm,whereas the thickness of areas such as the mental region and forehead have been approximated at 1375μm and 970μm respectively.[11]

Most recently, fractional photothermolysis (FP) has been introduced to address the shortcomings of the adverse side effects of ablative CO_2 and Er:YAG laser resurfacing and the limited efficacy of non-ablative laser resurfacing.[12] FP is a treatment modality characterized by the creation of microscopic zones or columns of thermal damage (termed microthermal zones, MTZ) with spatial separation between damaged tissue allowing more rapid re-epithelialization and patient recovery after treatment.[12,13] The islands of tissue spared by fractional resurfacing allow rapid wound healing by acting as a reservoir for epidermal stem cells and dermal fibroblasts the initiate the pathways for cutaneous remodeling.[12–14]

In 2007, Hantash et al.[15] described the first use of a novel "ablative" CO_2 fractional resurfacing device (ablative fractional photothermolysis, AFP) which produces an array of microthermal zones of a customizable density and depth. The primary difference between the first generation non-ablative fractional photothermolysis (NAFP) devices and AFP lies in the confluent array of ablation and coagulation extending from the stratum corneum to the mid reticular dermis with AFP.[15] In the initial in-vivo studies demonstrating the histologic and clinical effects of AFP, Hantash et al. confirmed with immunohistochemistry that persistent collagen remodeling occurred for at least three months post-treatment.[15] With the greater degree of injury of AFP, the authors predicted a greater and prolonged effect on induction of new collagen and remodeling of dermal collagen.[15] Several recent studies comparing NAFP with AFP, have demonstrated that AFP produces greater improvement in skin tightening and texture.[16,17]

Most recently in 2009, Rahman et al.[16] reported a high degree of safety and efficacy in photoaging with a prototype fractional AFP device (Reliant Technologies, Mountain View, CA). Patients were treated on both the face and neck at settings of 10 to 40mJ/MTZ and densities of 400 to 1,000 MTZ/cm^2. Even with these high fluences and treatment densities, the side effects experiences were limited to erthema, edema and mild crusting with no incidence of scarring or delayed onset hypopigmentation. Average improvements in indices of skin texture and tightening (on a quartile scale) in the series of 30 patients treated in this study were 2.30 (rhytides), 2.42 (texture) and 1.65 (laxity).

Given the efficacy reported in the literature for skin textural improvement with AFP technology, including improvements in skin tightening,[16–18] the authors set out to quantify specific improvements in skin texture, rhytides and laxity with a novel AFP device (Dermal Optical Thermolysis [DOT] Laser, Eclipse Med, Dallas, TX).

MATERIALS AND METHODS

The study protocol conformed to the guidelines of the 1975 Declaration of Helsinki and was approved by the St. Vincent Hospital Institutional Review Board and Ethics Committee, Carmel Indiana. Informed consent was obtained in writing from all patients prior to enrollment. All patients were required to be available for longitudinal study over the course of the study treatment and post-treatment evaluation. This period involved a pre-operative evaluation, a one-week post-operative visit, and a two-month post-treatment visit.

A prospective, controlled study for the treatment in 10 subjects presenting to our clinic for desired treatment of neck laxity between July 2008 and November 2008. Patients were excluded from the study if they had active infections, current pregnancy, a history of isotretinoin use in the year prior to laser treatment, a history of keloid scarring, known allergy to topical lidocaine anesthetic or any cosmetic procedure in the area(s) of treatment in the 12 months prior to the study.

The treatment area was thoroughly cleansed before the procedure with a gentle skin cleanser. A bupivicaine/lidocaine/tetracaine topical local anesthetic mix was applied 30 minutes before treatment. Treatment was administered to the neck with the Dermal Optical Thermolysis (DOT) Laser (Eclipse Med, Dallas TX), an AFP CO_2 laser (10,600 nm) at settings of 20 Watts, 500 pitch, 500 milliseconds. Forced cold air was administered during treatment for anesthesia utilizing the Zimmer Cooler device (LaserMed, Shelton, CT) at a setting of 5 at a distance of 3–4 inches from the skin surface. Patients received a series of one-to-three treatment sessions, given at six-to-eight week intervals. The number of treatment sessions was determined by the degree of clinical improvement with treatment.

Scoring Modality

A comprehensive grading scale encompassing and individually assessing gradations of severity for the various aspects of skin aging, including rhytides, laxity, texture and the various multiple components of photoaging was originally described by

Alexiades-Armenakas.[19] The authors utilized a modified version of this scale for neck laxity (Table 1) which was modified by our group to account for specific changes in neck rhytides, laxity, texture and overall cosmetic improvement.

At two months after the final treatment, blinded physician evaluation of photographs was utilized to assess the degree of improvement in four clinical indicators: rhytides, laxity, texture and overall cosmetic outcome. The modified neck laxity scale as described in Table 1 was utilized to assess all parameters. In addition, the degree of improvement was calculated as the percentage improvement between the initial treatment and the final visit at two months post-treatment.

Statistical Analysis

For each patient, the pre-treatment and post-treatment scores for each category were recorded, as were treatment number and final date of follow-up. Pre-treatment scores were recorded at baseline on the date of the first treatment. Post-treatment scores were recorded the date of final follow-up.

The percent change in score was calculated as the score difference divided by the baseline score. For each category (neck rhytides, laxity, texture and overall cosmetic improvement) the absolute score change, raw percentage change, mean percentage change and 95% confidence intervals (CI) were calculated. The percent of subjects showing improvement in each of the categories of the authors' Neck Laxity Scale (Table 1) was also calculated.

The paired t-test was utilized to test the change in each clinical indicator score (neck rhytides, laxity, texture and overall cosmetic improvement) from baseline to month 2 post-treatment. *P*-values less than 0.05 were considered statistically significant.

RESULTS

A total of 10 patients with neck laxity were treated with the Dermal Optical Thermolysis (DOT) Laser. Patients were seen for evaluation at both one week and at two months after the procedure. A comprehensive grading scale encompassing and individually assessing gradations of severity for the various aspects of skin aging, was originally described by Alexiades-Armenakas.[19] The authors utilized a modified version of this scale for neck laxity (Table 1) which was modified by our group to account for specific changes in neck rhytides, laxity, texture and overall cosmetic improvement.

Incidence of side effects of erythema, edema and pruritis were assessed at one week. The distribution, proportion, and descriptive statistics of all outcomes were considered.

TABLE 1.

Neck Laxity Scale

Grading Scale	Descriptive Parameter	Rhytides	Laxity	Texture
0	none	none	none	none
0.5	minimal	wrinkles with motion, 1–3, very superficial/ easily effaced	barely perceptible neck strands	focal subtle irregularity in 1–3 areas
1	mild	wrinkles with motion, few, superficial	early submandibular folds and neck strands	subtle irregularity
1.5	mild	wrinkles with motion, moderate number, superficial	early jowels, early submandibular folds and neck strands	mild irregularity in a few areas
2	moderate	wrinkles with motion, multiple superficial	early jowels, early submandibular folds	rough in a few localized areas
2.5	moderate	wrinkles at rest, multiple, localized, superficial	localized, indistinct jowels and early neck strands and submandibular folds	rough in several localized areas
3	advanced	wrinkles at rest, multiple, diffuse on neck, superficial	localized, prominent jowels and prominent submandibular folds, early neck strands	rough in multiple localized areas
3.5	advanced	wrinkles at rest, multiple, diffuse on neck, superficial and deep	prominent jowls and small, prominent neck strands and submandibular folds	mostly rough, little uninvolved skin
4	severe	wrinkles at rest, numerous, extensively distributed, deep	marked jowels, neck redundancy, submandibular folds and neck strands	rough throughout the neck

During treatment, patients reported minimal pain which was alleviated with the use of the topical and cold air anesthesia. Minimal post-operative erythema and edema were noted by patients which resolved within 48–72 hours post-treatment. Only one patient experienced prolonged erythema and pruritus which persisted at the one week post-treatment visit which resolved completely by one month post-treatment.

The number of treatment sessions required for significant improvement of neck tightening ranged from 1–3, with an average of 1.4 sessions (Table 2). For skin texture, the mean score decreased from 3.3 pre-treatment to a mean of 1.2 at two months post-treatment ($P<0.05$) for a 62.9% (57.4%, 68.4%) mean improvement. For skin laxity, the mean score decreased from 3.0 pre-treatment to 1.35 at two months post treatment ($P<0.05$), 57.0% (53.2%, 60.8%) mean improvement. For rhytides, the mean score decreased from 2.9 pre-treatment to 1.45 at two months post treatment ($P<0.05$), 51.4% (48.3%, 54.5%) mean improvement. For overall cosmetic outcome, mean score decreased from 3.25 pre-treatment 1.3 at two months post treatment ($P<0.05$), 59.3% (55.1%, 63.5%) mean improvement.

At two months after the final treatment, assessments indicated that 100% of patients had an improvement in skin texture, laxity, rhytides and overall cosmetic outcome of one point or greater (Table 3). Similarly, at two months after the final treatment, the majority of patients also had an improvement of 1.5 points or greater in the neck laxity scale. This response rate was 70% for skin texture, 100% for skin laxity, 60% for rhytides and 90% overall cosmetic outcome (90%) (Table 3).

Clinical pictures of patients demonstrating improvement in neck laxity are seen in Figures 1a and1b, Figures 2a and 2b, Figures 3a and 3b, Figures 4a and 4b, and Figures 5a and 5b.

FIGURE 1A-1B. Pre (left) and two months post (right) one treatment with ablative fractional photothermolysis (DOT Laser, Eclipse Med Inc.) in a 68-year-old Caucasian female.

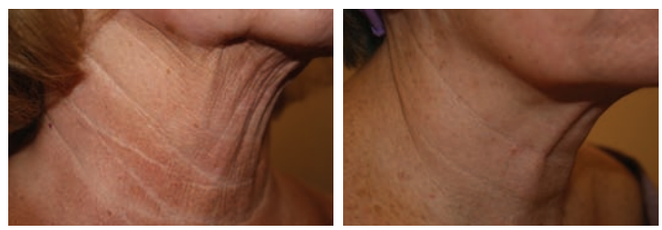

FIGURE 2A-2B. Pre (left) and two months post (right) one treatment with ablative fractional photothermolysis (DOT Laser, Eclipse Med Inc.) in a 68-year-old Caucasian female.

FIGURE 3A-3B. Pre (left) and two months post (right) one treatment with ablative fractional photothermolysis (DOT Laser, Eclipse Med Inc.) in a 71-year-old Caucasian female.

DISCUSSION

Laser and light-based treatments for skin tightening, have included ablative CO_2 and Er:YAG lasers, non ablative lasers and light devices, radiofrequency (RF) treatments and most recently, fractional photothermolysis (FP). These approaches have become increasingly popularized with the aging of the baby-boom generation and the concomitant greater societal acceptance and popularity of cosmetic procedures. Although the most dramatic results for skin tightening are achieved with surgical lifting procedures, these procedures require an extended recovery period and monetary expense, and carry significant risks. As such, non-invasive procedures with little post-operative morbidity, rapid recovery and a low-side effect profile are in demand.

The first laser based technology employed for skin tightening and texture improvement was ablative laser resurfacing.[1-8] The mechanism of action of ablative laser resurfacing for skin tightening is hypothesized to be that of immediate collagen contraction followed by delayed stimulation of collagen synthesis and remodeling.[1-8] However, due to the long-recovery times and risk of ablative resurfacing, particularly for non-facial skin, emphasis has more recently been placed on non-ablative, radiofrequency and fractional laser technologies.[1-8] One of the limitations of these non-ablative technologies is the need for multiple treatments, delayed and inconsistent improvement in skin laxity which do not parallel those seen after ablative resurfacing.[20] Several recent advances in treatment of skin laxity with AFP,[15-18] as reported herein, and with novel RF devices devices,[37-38] demonstrate greater promise in improvement of skin laxity and texture.

TABLE 2.

Quantitative Patient Improvement in Skin Texture, Laxity, Rhytids and Overall Cosmetic Outcome

	Age/Gender	Skin Texture	Skin Laxity	Rhytids	Overall Cosmetic Outcome
Patient #1	54 y/o Caucasian Female				
Pre-treatment		3	2	2	2.5
Post 3 treatments		0.5	0.5	1	1
% improvement		83%	75%	50%	60%
Patient #2	71 y/o Caucasian Female				
Pre-treatment		4	4	4	4
Post 1 treatment		0.5	1.5	1	1
% improvement		88%	63%	75%	75%
Patient #3	57 y/o Caucasian Female				
Pre-treatment		4	4	4	4
Post 2 treatments		2	2.5	2.5	2.5
% improvement		50%	38%	38%	38%
Patient #4	68 y/o Caucasian Female				
Pre-treatment		4	3.5	4	4
Post 1 treatment		1	1.5	2.5	1
% improvement		75%	57%	38%	75%
Patient #5	73 y/o Caucasian Female				
Pre-treatment		4	3.5	3.5	3
Post 1 treatment		2	2	2.5	1
% improvement		50%	43%	29%	67%
Patient #6	62 y/o Caucasian Female				
Pre-treatment		3	2.5	2	2.5
Post 2 treatments		1	1	0.5	1
% improvement		67%	60%	75%	60%
Patient #7	65 y/o Caucasian Female				
Pre-treatment		2	3	3	3
Post 1 treatment		1	1.5	1.5	1.5
% improvement		50%	50%	50%	50%
Patient #8	53 y/o Caucasian Female				
Pre-treatment		3	2	2	2.5
Post 1 treatment		1	0.5	1	1
% improvement		67%	75%	50%	60%
Patient #9	50 y/o Caucasian Female				
Pre-treatment		3	3	2	4
Post 1 treatment		1	1.5	1	1
% improvement		67%	50%	50%	75%
Patient #10	61 y/o Caucasian Female				
Pre-treatment		3	2.5	2.5	3
Post 2 treatments		2	1	1	2
% improvement		33%	60%	60%	33%

Mean Scores for All Patients	Texture	Skin Laxity	Rhytides	Overall Cosmetic Outcome
Pre-treatment	3.30	3.00	2.90	3.25
Post-treatment	1.20	1.35	1.45	1.30
P Value: pre- versus post-treatment score	p<.05	p<.05	p<.05	p<.05
Mean % improvement	62.9%	57.0%	51.4%	59.3%
95% confidence intervals	57.4%, 68.4%	53.2%, 60.8%	48.3%, 54.5%	55.1%, 63.5%

TABLE 3.

Number of Patients With Improvement in Neck Laxity		
Category	**Number of Patients**	**% Total**
Texture		
0.5 point improvement	10	100%
1 point improvement	10	100%
1.5 point improvement	7	70%
2+ point improvement	7	70%
Skin laxity		
0.5 point improvement	10	100%
1 point improvement	10	100%
1.5 point improvement	10	100%
2+ point improvement	2	20%
Rhytides		
0.5 point improvement	10	100%
1 point improvement	10	100%
1.5 point improvement	6	60%
2+ point improvement	1	10%
Overall Cosmetic Outcome		
0.5 point improvement	10	100%
1 point improvement	10	100%
1.5 point improvement	9	90%
2+ point improvement	4	40%

FIGURE 4A-4B. Pre (left) and two months post (right) one treatment with ablative fractional photothermolysis (DOT Laser, Eclipse Med Inc.) in a 71-year-old Caucasian female.

FIGURE 5A-5B. Pre (left) and two months post (right) one treatment with ablative fractional photothermolysis (DOT Laser, Eclipse Med Inc.) in a 73-year-old Caucasian female.

Deep-tissue heating with monopolar RF was one of the first modalities designed to tighten deeper dermal structures without epidermal damage.[21] Unlike a laser, which utilizes light energy to heat a targeted chromophore,[22] RF technology produces an electric current that generates heat through resistance in the dermis and subcutaneous tissue.[23] The RF devices, such as the ThermaCool (Thermage, Hayward, CA) use a unique capacitor membrane at the treatment tip that allows uniform, volumetric application of heat.[23-24] Simultaneous cooling by cryogen at the treatment tip allows concomitant protection of the epidermis during the deep heating of the dermis.[23-24]

Improvement in skin laxity with monopolar RF, as well as tolerability and side effect profile documented in the literature, have been highly variable.[21-28] The initial protocol with monopolar RF called for a single pass treatment at a relatively high-energy setting, resulting in second degree burns and fat atrophy in up to 2.7% of patients.[25] With more conservative energy settings and multiple passes (treatment energies 130J/cm^2 and 110J/cm^2 on the cheek and neck, respectively), Alster et al.[24] reported mean clinical improvements on 25–50% in submandibular and upper neck skin laxity after treatment with a monopolar RF device (ThermaCool; Thermage Corp., Hayward, CA). Fitzpatrick et al.[21] reported a series of 86 patients in which 80% demonstrated modest improvement in periorbital skin laxity and brow elevation after monopolar RF treatment. Ruiz-Esparza and Gomez[26] reported clinically significant tightening in 14/15 patients (93.3%) after a single RF treatment on the lower third of the face. Iyer et al.[27] found that 25/36 patients (70%) noticed significant improvement in skin laxity at 3 months after a single RF treatment. However, it was noted that 3/36 patients in this series developed superficial blistering after RF treatment. Finzi et al.[28] reported a series of 25 patients with mild to severe facial and neck laxity receiving one treatment session with a multipass vector technique with four to five passes. Efficacy reported in this study was significantly higher, where on evaluation of digital images, there was 96% cosmetic improvement in facial and neck laxity.

The degree of improvement of skin laxity with monopolar RF appears to vary significantly and is dependant upon both patient characteristics and treatment parameters.[21–28] Greater efficacy has been demonstrated in younger patients with mild to moderate laxity without significant underlying structural ptosis.[29] Patients with moderate to severe skin laxity have limited contour improvement after RF. Hsu and Kaminer[30] treated the lower face and neck in 16 patients with a single RF procedure. Only one-third of the patients in this study reported satisfactory results of improved skin tightening. Several trends emerged suggesting that younger patients and patients treated at higher energy levels had an improved clinical response. The authors attributed this finding to the fact that heat-labile collagen bonds are progressively replaced by irreducible multivalent cross-links as the skin ages, thus, older individuals are less amenable to the heat induced tissue tightening associated with RF.

A similar technology to RF, operating along the same principal of inducing deep dermal heating and collagen remodeling with concomitant epidermal cooling, is the use of infrared lasers (1100-1800 nm) in combination with skin surfacing cooling.[31] An experimental device with a 1310 nm wavelength and sapphire contact cooling was studied by Alexiades-Armenakas[32] and found to produce modest improvements in skin laxity, rhytides and texture. The selective heating at varying depths with this device overcomes the limitation of previous RF devices, where it is not possible to control the specific depth of the heated zone. After three months of follow-up with this device, 61% of subjects reported mild or better improvement in the laxity of the neck, 74% reported improvement of mild or better in the fine lines of the neck and 72% reported improvement of mild or better in the overall improvement of the appearance of the neck.

Most recently, a device combining optical energy and bipolar RF has been developed for facial skin rejuvenation,[33-35] where the synergistic effects of these two technologies was theorized to result in greater improvements in skin tightening However, studies to date have indicated that after a series of treatments at two-to-three week intervals, only modest improvements in skin tightening (25% improvement) are seen with this device.[36]

Future developments to enhance tightening with RF devices, include the recent development of an RF device with fine needle electrode tips.[37] In vitro work on human skin samples showed that RF exposure with this device caused thermal damage sufficient to cause marked collagen denaturation and shrinkage of virtually any diameter and depth as determined by the location of the probe.[37] Recently, a pilot clinical device based upon this concept of a bipolar microneedle device was demonstrated by Hantash et al.[38] to produce zones of denatured collagen within the reticular dermis. With the use of the microneedle approach to RF, heat was delivered in a "fractional pattern" where controlled heat was delivered to dermally located thermal coagulation zones, termed "radiofrequency thermal zones."[38] These new concepts of fractional delivery of RF and controlled heating based upon real-time feedback of temperature and impedance, may offer distinct advantages for the development of novel devices for skin tightening.

AFP, creating confluent columns of thermal damage in a random array extending from the stratum corneum to the mid dermis, has demonstrated significant effects of skin tightening and texture beyond that seen with the original NAFP devices.[15–18] The safety profile illustrated with AFP marks a significant advantage over traditional ablative laser resurfacing devices.[15–18] Patients are significantly more likely to undergo FP with the shorter post-operative recovery period and lesser risks of the procedure. Moreover, the safety profile of FP on non-facial areas, such as the neck, significantly surpasses that of traditional ablative resurfacing, where review of the literature reported herein demonstrates that neck resurfacing with CO_2 laser is complicated by up to 40% risk of scarring and 30% risk of delayed hypopigmentation.[1–8]

In our series, there was no incidence of scarring or post-inflammatory hyperpigmentation or hypopigmentation. One patient experienced prolonged erythema and pruritus which persisted at the one week post-treatment; however, this resolved completely by one month post-treatment. The safety profile and rapid healing with the FP device utilized in our study (DOT laser, Eclipse Med, Dallas TX), compares favorably with that reported in the literature for other AFP devices. A recent report by Rahman et al[18] with the Reliant prototype AFP device (Fraxel Re:pair, Reliant Technologies, Mountain View, CA) reported a 20% incidence of post-inflammatory hyperpigmentation. Similarly, Chapas et al.[39] reported a 16% incidence of post-inflammatory hyperpigmentation with the Reliant AFP device (Fraxel Re:pair, Reliant Technologies, Mountain View, CA) when treating for facial acne scarring. In a case report, Ross RB and Spencer J,[40] reported a case of scarring and persistent erythema after AFP, demonstrating that at high fluences and densities, similar adverse effects with AFP can be seen with those of traditional ablative devices.

One of the limitations of previous FP and RF devices is a lack of efficacy for deeper rhytides in older individuals with significant laxity of the face and neck. Notably, in this series, 60% of our patients had a skin laxity severity score of 3 or higher, associated with prominent jowls, prominent submandibular folds and neck strands. In these patients with extensive skin laxity, the mean percentage improvement in skin laxity was 50%, with notable improvement in neck jowls, strands and submandibular folds. In addition, previous treatments for skin laxity, rhytides and texture with fractionated resurfacing and RF have been suggested to have greater efficacy in younger individuals. However, in this series we did not find that older individuals or individuals with deeper, well established rhytides and jowels had lower efficacy of skin tightening. In this series, 40% of patients were 65 or older and notably, patients in this age cohort (65+), had improvements in overall cosmetic outcome which were significantly greater than that of the mean for this series, 66.7% versus 59.3% (P=.05).

CONCLUSION

AFP treatment of the neck demonstrated significant efficacy in both improvements of skin laxity and rhytides as well as surface texture. The texture of neck skin changes with aging of the skin from a smooth contour of uniform color to a rough texture often marked by skin creping and surface pigmentation or dyschromia. The decreased density of pilosebaceous units on the neck as well as the thinner dermis on the neck creates unique challenges where traditional ablative resurfacing results in prolonged wound healing and risks of scarring and dyspigmentation.[1–8,10]

The significant degree of clinical improvement in skin laxity and texture with AFP for the neck coupled with an excellent side effect profile, makes this an attractive alterative to surgical lifting procedures. In the future, further investigation is warranted to validate the results of our pilot study and to enhance our understanding and optimize treatment parameters of ablative fractionated resurfacing.

DISCLOSURES

Drs. Tierney and Hanke have no relevant conflicts of interest to disclose.

REFERENCES

1. Behroozan DS, Christian MM, Moy RL. Short-pulse carbon dioxide laser resurfacing of the neck. *J Am Acad Dermatol*. 2000;43(1 Pt 1):72-76.
2. Fitzpatrick RE, Goldman MP. Resurfacing of photodamage of the neck using the Ultrapulse CO_2 laser (abstract). *Lasers Surg Med*. 1997;Suppl 9:33.
3. Kilmer SL, Chotzen VA, Silva SK, McClaren ML. Safe and effective carbon dioxide laser skin resurfacing of the neck. *Lasers Surg Med*. 2006;38(7):653-657.
4. Jimenez G, Spencer JM. Erbium:YAG laser resurfacing of the hands, arms, and neck. *Dermatol Surg*. 1999;25(11):831-834.
5. Goldberg DJ, Meine JG. Treatment of photoaged neck skin with the pulsed Erbium:YAG laser. *Dermatol Surg*. 1998;24(6):619-621.
6. Goldman MP, Fitzpatrick RE, Manuskiatti W. Laser resurfacing of the neck with the Erbium: YAG laser. *Dermatol Surg*. 1999;25(3):164-167.
7. Fanous N, Prinja N, Sawaf M. Laser resurfacing of the neck: A review of 48 cases. *Aesthetic Plast Surg*. 1998;22(3):173-179.
8. Rosenberg GJ. Full face and neck laser skin resurfacing. *Plast Reconstr Surg*. 1997;100(7):1846-1854.
9. Rossiter JL. Dermabrasion: Clinical uses in otolaryngology. *J Otolaryngol*. 1994;23(5):347-353.
10. Salasche SJ, Bernstein G, Senkarik M. Surgical Anatomy of the Skin. Norwalk (CT): *Appleton & Lange*; 1988.
11. Gonzalez-Ulloa M, Castillo A, Stevens E, et al. Preliminary study of the total restoration of the facial skin. *Plast Reconstr Surg*. 1954;13(3):151-161.
12. Manstein D, Herron GS, Sink RK, et al. Fractional photothermolysis: A new concept for cutaneous remodeling using microscopic patterns of thermal injury. *Lasers Surg Med*. 2004;34(5):426-438.
13. Laubach H, Chan HH, Rius F, et al. Skin responses to fractional photothermolysis. *Lasers Surg Med*. 2006;38(2):142-149.
14. Walgrave S, Zelickson B, Childs J, et al. Pilot investigation of the correlation between histological and clinical effects of infrared fractional resurfacing lasers. *Dermatol Surg*. 2008;34(11):1443-1153.
15. Hantash BM, Bedi VP, Kapadia B, et al. In vivo histological evaluation of a novel ablative fractional resurfacing device. *Lasers Surg Med*. 2007;39(2):96-107.
16. Weiss R, Weiss M, Beasley K. Prospective split-face trial of a fixed spacing array computed scanned fractional CO_2 laser versus hand scanned 1550 nm fractional for rhytides. Abstract presented at American Society for Laser Medicine and Surgery Conference, April 2008, Kissimee, FL.
17. Lomeo G, Cassuto D, Scrimali L, Sirago P. Er:YAG versus CO_2 ablative fractional resurfacing: a split face study. Abstract presented at American Society for Laser Medicine and Surgery Conference, April 2008, Kissimee, FL.
18. Rahman Z, MacFalls H, Jiang K, et al. Fractional deep dermal ablation induces tissue tightening. *Lasers Surg Med*. 2009;41(2):78-86.
19. Alexiades-Armenakas M. A quantitative and comprehensive grading scale for rhytides, laxity, and photoaging. *J Drugs Dermatol*. 2006;5(8):808-809.
20. Alexiades-Armenakas MR, Dover JS, Arndt KA. The spectrum of laser skin resurfacing: Nonablative, fractional, and ablative laser resurfacing. *J Am Acad Dermatol*. 2008;58(5):719-737.
21. Fitzpatrick R, Geronemus R, Goldberg D, et al. Multicenter study of noninvasive radiofrequency for periorbital tissue tightening. *Lasers Surg Med*. 2003;33(4):232-242.
22. Anderson RR, Parrish JA. Selective photothermolysis: Precise microsurgery by selective absorption of pulsed radiation. *Science*. 1983;220(4596):524-527.
23. Tunnel JW, Pham L, Stern RA, et al. Mathematical model of nonablative RF heating of skin. *Lasers Surg Med*. 2002;14(Suppl):318.
24. Alster TS, Tanzi E. Improvement of neck and cheek laxity with a nonablative radiofrequency device: A lifting experience. *Dermatol Surg*. 2004;30(4 Pt 1):503-507.
25. de Felipe I, Del Cueto SR, Pérez E, Redondo P. Adverse reactions after nonablative radiofrequency: Follow-up of 290 patients. *J Cosmet Dermatol*. 2007;6(3):163-166.
26. Ruiz-Esparza J, Gomez JB. Nonablative radiofrequency for active acne vulgaris: The use of deep dermal heat in the treatment of moderate to severe active acne vulgaris (thermotherapy): A report of 22 patients. *Dermatol Surg*. 2003;29(4):333-339.
27. Iyer S, Suthamjariya K, Fitzpatrick RE. Using a radiofrequency device to treat the lower face: a treatment paradigm for a non surgical face lift. *Cosmet Dermatol*. 2003;16:37-40.
28. Finzi E, Spangler A. Multipass vector (mpave) technique with nonablative radiofrequency to treat facial and neck laxity. *Dermatol Surg*. 2005;31(8 Pt 1):916-922.
29. Dierickx CC. The role of deep heating for noninvasive skin rejuvenation. *Lasers Surg Med*. 2006;38(9):799-807.
30. Hsu TS, Kaminer MS. The use of nonablative radiofrequency technology to tighten the lower face and neck. *Semin Cutan Med Surg*. 2003;22(2):115-123.
31. Alexiades-Armenakas M. Assessment of the mobile delivery of infrared light (1100-1800 nm) for the treatment of facial and neck skin laxity. *J Drugs Dermatol*. 2009;8(3):221-226.
32. Alexiades-Armenakas M. Nonablative skin tightening with a variable depth heating 1310-nm wavelength laser in combination with surface cooling. *J Drugs Dermatol*. 2007;6(11):1096-1103.
33. Sadick NS, Alexiades-Armenakas M, Bitter P Jr, et al. Enhanced full-face skin rejuvenation using synchronous intense pulsed optical

and conducted bipolar radiofrequency energy (ELOS): Introducing selective radiophotothermolysis. *J Drugs Dermatol*. 2005;4(2):181-186.

34. Sadick N. Bipolar radiofrequency for facial rejuvenation. *Facial Plast Surg Clin North Am*. 2007;15(2):161-167.
35. Alexiades-Armenakas M. Rhytides, laxity, and photoaging treated with a combination of radiofrequency, diode laser, and pulsed light and assessed with a comprehensive grading scale. *J Drugs Dermatol*. 2006;5(8):731-738.
36. Doshi SN, Alster TS. Combination radiofrequency and diode laser for treatment of facial rhytides and skin laxity. *J Cosmet Laser Ther*. 2005;7(1):11-15.
37. Laubach HJ, Manstein D. Histologic evaluation of minimally invasive radiofrequency exposure. *Lasers Surg Med*. 2006;S18-S28.
38. Hantash BM, Renton B, Berkowitz RL, et al. Pilot clinical study of a novel minimally invasive bipolar microneedle radiofrequency device. *Lasers Surg Med*. 2009;41(2):87-95.
39. Chapas AM, Brightman L, Sukal S, et al. Successful treatment of acneiform scarring with CO_2 ablative fractional resurfacing. *Lasers Surg Med*. 2008;40(6):381-386.
40. Ross RB, Spencer J. Scarring and persistent erythema after fractionated ablative CO_2 laser resurfacing. *J Drugs Dermatol*. 2008;7(11):1072-1073.

ADDRESS FOR CORRESPONDENCE

C. William Hanke, MD, MPH
13400 N. Meridian Street, Suite 290
Carmel, IN 46032
Phone: ..... (317) 660-4900
Fax: ..... (317) 660-4901
E-mail: ..... cwmhanke@sbcglobal.net