

Efficacy of Fractional Microneedle Radiofrequency Device in the Treatment of Primary Axillary Hyperhidrosis: A Pilot Study

Miri Kim^a Jae Yong Shin^b Jungsoo Lee^b Ji Young Kim^b Sang Ho Oh^b

^aDepartment of Dermatology, St. Mary's Hospital, College of Medicine, Catholic University of Korea, and

^bDepartment of Dermatology and Cutaneous Biology Research Institute, Yonsei University College of Medicine, Seoul, Korea

Key Words

Fractional microneedle radiofrequency · Axillary hyperhidrosis

Abstract

Background: Fractional microneedle radiofrequency (FMR) devices deliver energy to the deep dermis through insulated microneedles without destroying the epidermis. These FMR devices have been shown to be effective for the treatment of wrinkles, acne scars and large pores. In this study it was postulated that FMR energy could specifically affect the sweat glands, preserving the skin surface even if sweat glands were seated in the deep dermis. **Objective:** To evaluate the efficacy and safety of FMR for primary axillary hyperhidrosis (PAH) treatment and to conduct a histological analysis before and after treatment. **Methods:** Twenty patients with PAH had 2 sessions of bipolar FMR treatment at 4-week intervals. Clinical improvement was evaluated using a Hyperhidrosis Disease Severity Scale (HDSS) and photographs were taken using the starch-iodine test at every visit and 2 months after the last treatment. The amount of sweat reduction was indirectly assessed using a TewameterTM. Skin biopsies were obtained from 3 of the enrolled patients before and after treatment. The satisfaction and adverse reactions of the research participants were recorded at every follow-up visit. **Results:** HDSS scores decreased significantly

from a baseline of 3.3 to 1.5 and 1.8 after the first and second months of posttreatment follow-up sessions, respectively ($p < 0.001$). In response to a subjective assessment at 1 month after the second treatment, 75% of patients ($n = 15$) had an HDSS score of 1 or 2, and 70% of patients ($n = 14$) expressed more than 50% improvement in their sweating. The starch-iodine reaction was also remarkably reduced in 95% of patients ($n = 19$) after FMR treatment. Histological findings showed a decrease in the number and size of both apocrine and eccrine glands 1 month after the final treatment. Side effects were minimal and included mild discomfort, transient swelling and postinflammatory hyperpigmentation. **Conclusion:** FMR treatment was effective for the treatment of PAH without significant adverse reactions due to direct volumetric heating of the lower dermis.

© 2013 S. Karger AG, Basel

Introduction

Primary axillary hyperhidrosis (PAH), which presents with excessive sweating restricted to the axillary area without any recognizable cause, can greatly affect social and psychological well-being. Many treatment modalities have been developed to address axillary hyperhidrosis and have had variable effects, which have depended on the severity of sweating and the demands of pa-

tients. These treatments have included topical aluminum salts, iontophoresis, systematic anticholinergic administration, and various laser devices and surgical procedures [1–8]. Out of the various laser therapies, subdermal 1,064-nm Nd:YAG and 1,320-nm laser treatments have been reported to treat PAH effectively [4, 5]. However, potential risks of these methods include burning and symptom recurrence. Botulinum toxin therapy is now widely used for PAH, but limitations of this treatment such as financial cost and transient results must be considered [9–11]. Recently, Hong et al. [12] reported that microwave devices had long-term effects (12 months) on the treatment of PAH by heating at the interface between the epidermis and subcutaneous tissue and causing irreversible thermolysis of apocrine and eccrine sweat glands. Fractional microneedle radiofrequency (FMR) is a recently developed, minimally invasive method for delivering thermal energy to the target tissue without destroying the epidermis, by using rapid penetration with microneedles. FMR treatment has demonstrated excellent efficacy for skin rejuvenation, face lifting, large pores and acne scars [13–16]. Therefore, we postulated that FMR could be considered as an alternative treatment for PAH on a similar principle of microwave devices, and to test this hypothesis, we prospectively evaluated the efficacy of the FMR device as a therapeutic option for PAH.

Materials and Methods

Patients

Twenty PAH patients with symptoms that warranted intervention, defined as having a score of 3 or 4 on a Hyperhidrosis Disease Severity Scale (HDSS), were enrolled in the study (17 women, 3 men; mean age: 30.5 years; range: 19–46 years; Fitzpatrick skin type IV). Patients that had undergone concomitant therapies in the past 12 months, such as surgery for axillary hyperhidrosis or botulinum toxin injections in the axillae, were not included in this study. The study also excluded patients with a history of pacemaker implantation or keloid formation and those who were pregnant or diagnosed with systemic diseases that affect metabolism. This study was approved by the institutional review board of Severance Hospital, Seoul, Korea, and written informed consent was obtained from all study subjects prior to enrollment.

Treatment Protocol

Each patient had 2 sessions of FMR treatment using a novel applicator (Infini™; Lutronic, Goyang, Korea) at 4-week intervals. This applicator consists of rows of 49 insulated microneedles over an area of 10 mm² that form an array of positively and negatively charged electrodes. The microneedles delivered bipolar radiofrequency energy in a fractional manner that extended from 0.5 to 3.5 mm below the surface of the skin. These bipolar electrode pins formed a closed circuit through the irradiated skin and delivered

Table 1. Hyperhidrosis Disease Severity Scale

HDSS score	Definition
1	My axillary sweating is never noticeable and never interferes with my daily activities.
2	My axillary sweating is tolerable but sometimes interferes with my daily activities.
3	My axillary sweating is barely tolerable and frequently interferes with my daily activities.
4	My axillary sweating is intolerable and always interferes with my daily activities.

1 MHz of radiofrequency current conducted to the skin. Energy levels of up to 20 J can be delivered with a 5% or 10% coverage rate, according to program selection, through a 200-mm-diameter pin, and the energy deposition occurs in 0.01–1 s. An adjustable radiofrequency voltage up to a maximum of 50 V can be delivered, in relation to radiofrequency treatment level (1–20) and conduction time (10–1,000 ms). All subjects were pretreated by local tumescent anesthesia in the axillae, according to Klein's formula (0.05–0.1% lidocaine, 1:1,000 epinephrine and 10 mEq/l sodium bicarbonate added to each liter of normal saline) prior to FMR treatment to reduce heat damage to the skin and induce numbness. The skin was cleansed with alcohol and allowed to dry completely. The target areas were treated with a total of 6 passes and included passes with stacked pulses. The treatment included the following parameters: (1) the first 2 passes were at a depth of 3.5 mm for 150 ms, at energy level 10 (25 V); (2) the second 2 passes were at a depth of 3.0 mm for 150 ms, at energy level 10 (25 V); and (3) the last 2 passes were at a depth of 2.5 mm for 150 ms, at energy level 10 (25 V). The preferred irradiation end point was when petechiae were visible within the targeted area. Ice packs were applied during treatment and for 10 min after FMR therapy to reduce heat damage to the epidermal skin. This was followed by hydrocolloid dressing with DuoDerm™ Extra Thin (ConvaTec, Princeton, N.J., USA).

Outcome Assessments

Starch-iodine tests and HDSS assessment were performed to measure the disease severity of PAH at every visit and again at 2 months after the last treatment. The four possible scores are defined in table 1. The starch-iodine test was used to outline the area of excessive sweating and to qualitatively identify sweat reduction. For this procedure, iodine solution was applied to a dry surface on the skin, and then corn starch was sprinkled over the area. The patients were asked to exercise by either running or walking for 10 min in a room at 20°C, which caused the patients to sweat. The starch and iodine interact in the presence of sweat, which leaves a blue-black sediment (fig. 1). The photographs of the starch-iodine test were taken to assess the extent and severity of sweating, which was determined by the margin and degree of discoloration. Trans-epidermal water loss (TEWL), which can be used to determine the amount of sweat, was measured by a Tewameter™ (Courage +

Table 2. Patient demographics

Median age, years (range)	30.5 (19–46)
Sex, n (%)	
Male	3 (15)
Female	17 (85)
Ethnicity, n (%)	
Asian	20 (100)
Baseline HDSS score, n (%)	
3	12 (60)
4	8 (40)

Khazaka electronic GmbH, Köln, Germany) [17–19]. Prior to the measurements, patients were at rest in an ambient-temperature room for 10 min.

Histological evaluations were conducted before and after treatment on 3 enrolled patients that had given their consent for skin biopsies. Skin samples were obtained via a 4-mm punch biopsy which was taken at baseline, immediately after the first treatment session, 1 month after the first treatment session and 1 month after the second treatment. Posttreatment biopsy specimens were taken from locations near the previous biopsy sites. Patients were asked to document their perception of overall improvement, and patient satisfaction was evaluated using a 5-point scale with the following specifications: 0 = no improvement; 1 = <25% improvement; 2 = 25–50% improvement; 3 = 51–75% improvement; and 4 = >75% improvement. At each visit, the patients were also asked to report any side effects such as bleeding, oozing, pain, erythema or purpura and compensatory hyperhidrosis.

Statistical Analysis

Statistical analysis was conducted with SPSS software version 12.0 (SPSS Inc., Chicago, Ill., USA). Paired *t* tests and repeated-measures ANOVA was used to compare clinical results at each follow-up visit. All *p* values were two-sided and statistical significance was defined as *p* < 0.05.

Results

The characteristics of the 20 patients involved in this study are summarized in table 2. The starch-iodine test demonstrated that the size of the affected area decreased remarkably in 19 of the patients after treatment (fig. 1). The mean HDSS baseline scores 4 weeks after the first treatment, 4 weeks after the second treatment and 8 weeks after the second treatment were 3.5, 1.5, 1.8 and 2.3, respectively. Additionally, there was a significant decrease in the amount of sweating (*p* < 0.001) (fig. 2). The TEWL values decreased 4 weeks after the first treatment, but unexpectedly increased when measured 4 and 8 weeks after the second treatment (*p* > 0.05) (fig. 3).

The patient surveys indicated that 70% of the patients (14/20) answered that they experienced more than 50% improvement in sweating 4 weeks after the first treatment session; 60% of the patients (12/20) and 30% of the patients (6/20) answered that they experienced more than 50% improvement in sweating 4 weeks and 8 weeks after the second treatment session, respectively. All patients expressed at least more than 25% satisfaction with the treatment. The mean patient satisfaction scores were 3.3, 3.0 and 2.05 at 4 weeks after the first treatment, and at 4 weeks and 8 weeks after the second treatment, respectively.

Baseline histological examination identified sweat gland lobules which started at a mean depth of 2.3 mm (range: 2–3 mm) from the skin surface and stopped at the bottom of the histological specimen. From these data, glandular structures were located in the deep skin at a range between 2 and 4 mm (mean: 3.5 mm). Skin specimens obtained immediately after the first treatment session showed an intact epidermis with traces of micro-needles and coagulation. However, collagen degeneration and hemorrhage were visible between 2.5 and 3.5 mm depths in the deep dermis, where there was radiofrequency from the tip of the microneedles. Atrophy and necrosis of glands were found under high magnification (fig. 3a). One month after the first treatment session, there was a decrease in the density and size of apocrine and eccrine glands when compared with the glands prior to treatment (fig. 3b, c).

No major adverse effects such as scarring and burning were experienced with the FMR treatment. In most patients, temporary side effects such as tingling, swelling and redness were observed in the affected areas, but these problems were resolved within 1 week of the treatment. Two patients experienced compensatory hyperhidrosis, the upper lip and chin were affected in one patient, and the forehead and back were affected in the other patient. Another patient complained of numbness of her right arm, which was resolved within 3 weeks of treatment.

Discussion

Radiofrequency energy provides tissue heating, depending on the specific tissue resistance; it has been used clinically in surgery, oncology, cardiology and other fields of medicine. In the field of dermatology, radiofrequency was first used for skin tightening to promote collagen restructuring and neocollagenesis by disrupting the overlying epidermis [13, 15]. The combination of radiofrequen-

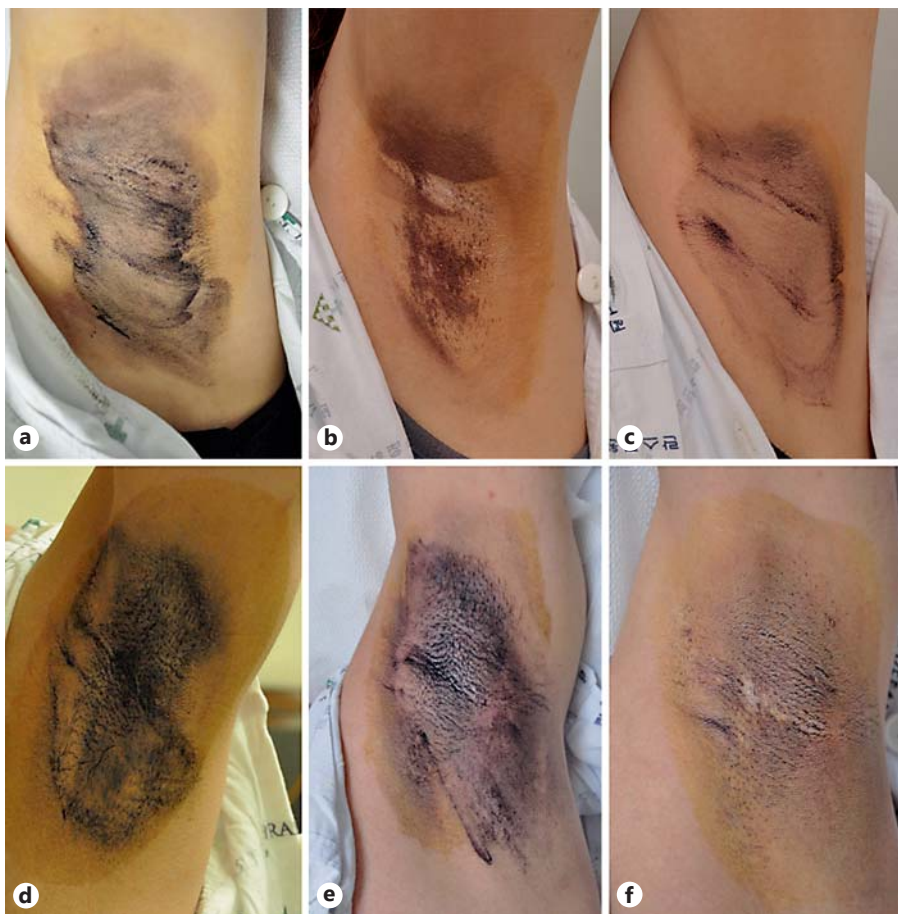

Fig. 1. Starch-iodine photographs before and after FMR treatment. Patient 1 (a–c) and patient 2 (d–f) at baseline (a, d), 1 month after the first treatment (b, e) and 2 months after the second treatment (c, f).

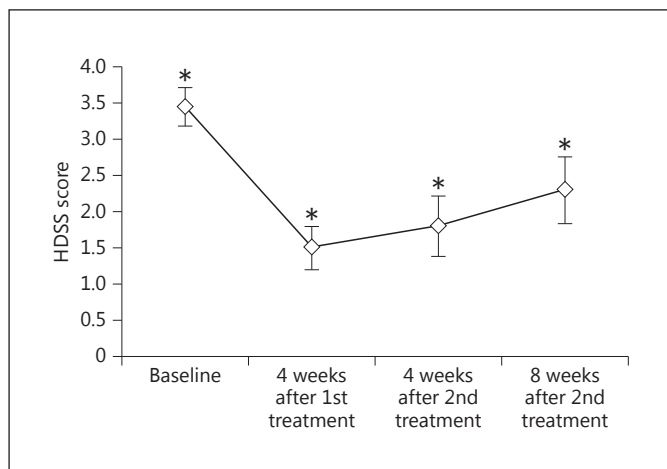
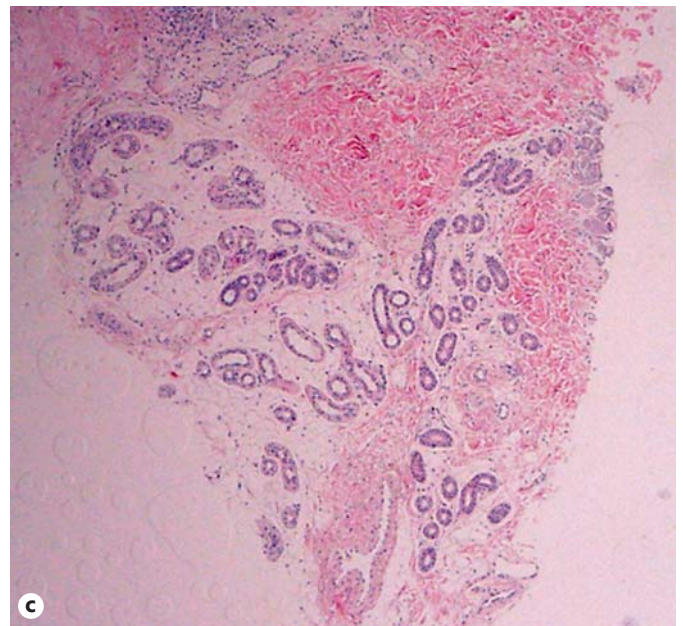
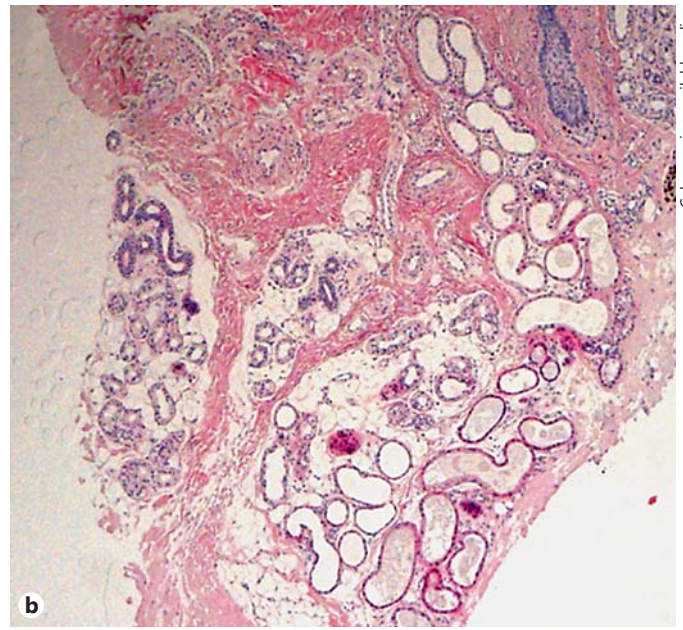
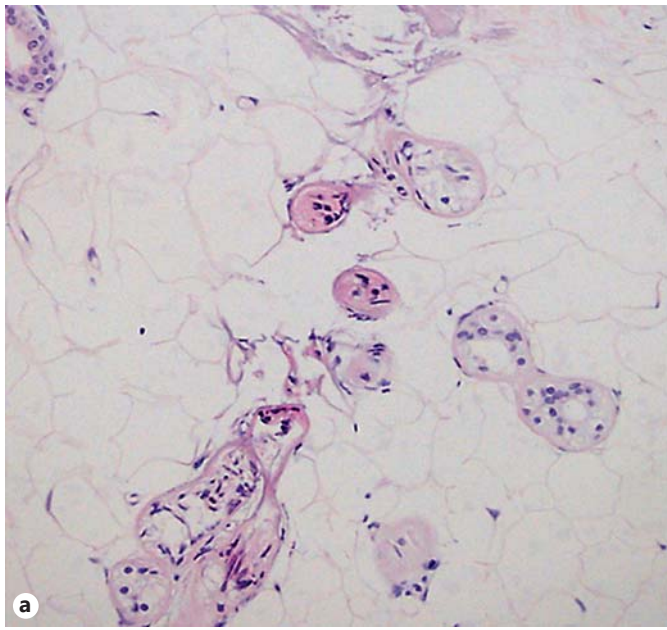


Fig. 2. Average HDSS scores \pm standard deviation at each follow-up visit. * $p < 0.05$, after repeated-measures ANOVA.

cy and fractional microneedle technology creates an effective method, with a better safety profile, for treating various dermatologic conditions. The Kobayashi insulated needle, which selectively destroys intradermal target lesions such as hair and sweat glands, has been very effective in reducing hair and sweat, but the procedure was not widely performed because of the time it requires [20, 21]. One advantage of the FMR device is that the depth of radiofrequency thermal zones can be controlled and adjusted to a desired target without causing skin damage. Because of this, it was hypothesized that FMR could be used to destroy sweat glands and applied as an effective treatment for PAH.

Recently, a noninvasive treatment method has been identified for PAH that involves a novel microwave device which heats the interface between the lower dermis and the subcutaneous fat layer [12]. By applying this technology, it was postulated that the FMR device, which creates pyramid-shaped fractionated thermal zones depending on the impedance of tissue, could be used to specifically



Color version available online

Fig. 3. Biopsy specimens after FMR treatment. **a** Skin samples obtained immediately after FMR treatment. At high magnification ($\times 200$), coagulation changes of the glands and dermis due to heat damage were observed. **b** Skin samples from baseline (before treatment) to 4 weeks after the second treatment sessions. **c** A decrease in the number and size of both apocrine and eccrine glands after treatment was observed. $\times 40$.

damage sweat glands. In this study, the efficacy of FMR treatment was assessed by a reduction in HDSS scores, where efficacy was evaluated as the percentage of patients that reached an HDSS score of 1 or 2. A study that used botulinum toxin found that 4 and 12 weeks after treatment, 85% (121/142) and 90% (115/128) of patients, respectively, had reached an HDSS score of 1 or 2 [22]. In this study, 4 and 8 weeks after the second treatment session, 75% (15/20) and 60% (12/20) of the patients, respec-

tively, reached an HDSS score of 1 or 2. When the different environmental possibilities that could affect HDSS assessment are considered, FMR application was a significant improvement for PAH treatment, even if FMR was slightly less effective after treatment when compared with the botulinum toxin injection study. In this study, the HDSS score decreased from a baseline of 3.5 to 1.5 at 4 weeks after the first treatment. Then, after the second treatment, around the hot and humid late summer season, HDSS

scores gradually increased to 1.8 and then to 2.3. Nevertheless, the final score was lower than the score of 3.5 at baseline, which suggests that FMR is effective in reducing the amount of sweat. Although we did not check tissue resistance exactly, tumescent anesthesia, which was used to reduce heat damage to the skin and to reduce pain during therapy, is presumed to decrease the effect of FMR treatment by altering energy deposition and heating patterns [23]. Therefore, even though topical numbing cream does not affect tissue impedance, because of the application of the topical cream, FMR could maximize heat delivery to sweat glands, which could lead to an augmentation of the effects of FMR on PAH when compared with botulinum toxin. However, because FMR therapy directly damages sweat glands, FMR was expected to have a lasting effect on sweat reduction compared with botulinum toxin.

The TEWL level was measured to evaluate the amount of sweating for each patient. This technique was based on several studies which have used TEWL to determine the effects of antiperspirants for hyperhidrosis [17–19]. In our study, we used the Tewameter for the patients' convenience and to simplify the procedures performed in the outpatient clinic. We observed a statistically significant decrease in TEWL 1 month after the first treatment session, and this method suggests its possible use as an appropriate tool for the evaluation of postprocedural sweating in future studies. However, there was a gradual TEWL increase after the second treatment session and during the follow-up period. This result could be attributed to seasonal variations and damage to the skin barrier that was inflicted by FMR treatment. This study began in early summer and came to an end in the middle of summer. TEWL can be affected by environmental factors such as air convection, ambient temperature and relative humidity as well as seasonal variation [24]. Even if we made our best effort to keep the environment of the room where we measured TEWL the same at each visit, the hot and humid late summer season, which is when we measured TEWL after the second treatment, may have increased the level of TEWL.

The histopathologic findings indicate that FMR reduces sweating by causing direct heat damage and destroying the glands. The radiofrequency from the tips of the microneedles causes direct thermal injury which decreases the size and density of the apocrine glands. The microneedle penetration depth in our study was designed to reach between 2.5 and 3.5 mm. This depth was based on a previous study which found that apocrine and eccrine glands were in close apposition and that glandular tissues occupied an average thickness of 3.5 mm of skin [25]. As a

result, the mean coagulation depth in the skin specimens was 2.5 mm, and coagulation necrosis of sweat glands was observed immediately after treatment, as well as a reduction in the size and number of sweat glands during the follow-up period. However, the existence of sweat glands after treatment could indicate the possibility of recurrence after long-term follow-up, and the need for additional treatment sessions. A few patients experienced a reduction in foul odor production and decreased sweating after FMR treatment. This result corresponds with previous results that apocrine and eccrine glands both exist on the same level of the skin layer [25].

In addition, since there were 3 patients with either axillary numbness ($n = 1$) or compensatory hyperhidrosis ($n = 2$), the treatment might have caused changes in the nervous supply to the local tissues. These changes are likely the result of direct nerve injury, due to deep needle penetration, and are a secondary effect of thermal injury. The most common side effects in this study were transient swelling and postinflammatory hyperpigmentation. These side effects were mild, tolerable and disappeared completely within 2 weeks of treatment. The exact mechanism of compensatory hyperhidrosis, which occurred in 2 patients in this study, has not yet been elucidated. The compensatory sweating may be a thermoregulatory mechanism of the sweat glands to adjust for the loss of secretory tissue [26, 27].

There are several limitations to this study, such as the small sample size, short observation period, lack of standardization of energy delivery, and inability to regulate the environment for sweating assessment. There are several variables that could affect sweat production, such as the environment including temperature and humidity, seasonal conditions, and the physiologic and psychological conditions of each patient. These variables could affect the tests that were used to assess patient sweating, including the starch-iodine test, the Tewameter and subjective satisfaction responses. However, this study attempted to control the influences of these variables when assessing patient sweat production. Additionally, this was a pilot study, so it will be essential for future studies to establish suitable parameters for PAH treatment, such as the amount of energy applied, the depth of needle penetration, the number of passes in one session of treatment, and the treatment interval and number of treatment sessions. The importance of this pilot study lies in observing the clinical and histopathological effect of FMR treatment in axillary hyperhidrosis, which has not been studied before as it was conventionally used to treat cosmetic wrinkles or acne scars.

Based on the results, FMR could be a promising new treatment modality for axillary hyperhidrosis. In the future, to maximize the effect of FMR therapy on PAH, further studies should be performed with well-established parameters and suitable numbers of patients and treatment intervals.

Acknowledgments

This study was supported by health technology transfer and industry development support from the Ministry of Health and Welfare.

Disclosure Statement

The authors declare no conflict of interest.

References

- 1 Atkins JL, Butler PE: Hyperhidrosis: a review of current management. *Plast Reconstr Surg* 2002;110:222–228.
- 2 Stolman LP: Treatment of excess sweating of the palms by iontophoresis. *Arch Dermatol* 1987;123:893–896.
- 3 Bechara FG, Georgas D, Sand M, Stücker M, Othlinghaus N, Altmeyer P, Gambichler T: Effects of a long-pulsed 800-nm diode laser on axillary hyperhidrosis: a randomized controlled half-side comparison study. *Dermatol Surg* 2012;38:736–740.
- 4 Goldman A, Wollina U: Subdermal Nd-YAG laser for axillary hyperhidrosis. *Dermatol Surg* 2008;34:756–762.
- 5 Kotlus BS: Treatment of refractory axillary hyperhidrosis with a 1,320-nm Nd:YAG laser. *J Cosmet Laser Ther* 2011;13:193–195.
- 6 Bechara FG, Altmeyer P, Sand M, Hoffmann K: Surgical treatment of axillary hyperhidrosis. *Br J Dermatol* 2007;156:398–399.
- 7 Unal O, Citgez B, Battal M, Karatepe O: Single incision thoracoscopic sympathectomy for hyperhidrosis. *BMJ Case Rep* 2012;2012.
- 8 Bechara FG, Sand M, Tomi NS, Altmeyer P, Hoffmann K: Repeat liposuction-curettage treatment of axillary hyperhidrosis is safe and effective. *Br J Dermatol* 2007;157:739–743.
- 9 Hoorens I, Ongenaes K: Primary focal hyperhidrosis: current treatment options and a step-by-step approach. *J Eur Acad Dermatol Venereol* 2012;26:1–8.
- 10 Bushara KO, Park DM, Jones JC, Schutta HS: Botulinum toxin: a possible new treatment for axillary hyperhidrosis. *Clin Exp Dermatol* 1996;21:276–278.
- 11 Doft MA, Hardy KL, Ascherman JA: Treatment of hyperhidrosis with botulinum toxin. *Aesthet Surg J* 2012;32:238–244.
- 12 Hong HC, Lupin M, O'Shaughnessy KF: Clinical evaluation of a microwave device for treating axillary hyperhidrosis. *Dermatol Surg* 2012;38:728–735.
- 13 Alster TS, Lupton JR: Nonablative cutaneous remodeling using radiofrequency devices. *Clin Dermatol* 2007;25:487–491.
- 14 Elsaie ML, Choudhary S, Leiva A, Nouri K: Nonablative radiofrequency for skin rejuvenation. *Dermatol Surg* 2010;36:577–589.
- 15 Lolis MS, Goldberg DJ: Radiofrequency in cosmetic dermatology: a review. *Dermatol Surg* 2012;38:1765–1776.
- 16 Cho SI, Chung BY, Choi MG, Baek JH, Cho HJ, Park CW, Lee CH, Kim HO: Evaluation of the clinical efficacy of fractional radiofrequency microneedle treatment in acne scars and large facial pores. *Dermatol Surg* 2012;38:1017–1024.
- 17 van Houte M, Harmsze AM, Deneer VH, Tupker RA: Effect of oxybutynin on exercise-induced sweating in healthy individuals. *J Dermatolog Treat* 2008;19:101–104.
- 18 Pinnagoda J, Tupker RA, Coenraads PJ, Nater JP: Transepidermal water loss with and without sweat gland inactivation. *Contact Dermatitis* 1989;21:16–22.
- 19 Goh CL: Aluminum chloride hexahydrate versus palmar hyperhidrosis: evaporimeter assessment. *Int J Dermatol* 1990;29:368–370.
- 20 Kobayashi T: Electrosurgery using insulated needles: epilation. *J Dermatol Surg Oncol* 1985;11:993–1000.
- 21 Kobayashi T: Electrosurgery using insulated needles: treatment of axillary bromhidrosis and hyperhidrosis. *J Dermatol Surg Oncol* 1988;14:749–752.
- 22 Solish N, Benohanian A, Kowalski JW, Canadian Dermatology Study Group on Health-Related Quality of Life in Primary Axillary Hyperhidrosis: Prospective open-label study of botulinum toxin type A in patients with axillary hyperhidrosis: effects on functional impairment and quality of life. *Dermatol Surg* 2005;31:405–413.
- 23 Hantash BM, Renton B, Berkowitz RL, Stridde BC, Newman J: Pilot clinical study of a novel minimally invasive bipolar microneedle radiofrequency device. *Lasers Surg Med* 2009;41:87–95.
- 24 Lawrence CM, Lonsdale Eccles AA: Selective sweat gland removal with minimal skin excision in the treatment of axillary hyperhidrosis: a retrospective clinical and histological review of 15 patients. *Br J Dermatol* 2006;155:115–118.
- 25 Grice K, Sattar H, Baker H: The effect of ambient humidity on transepidermal water loss. *J Invest Dermatol* 1972;58:343–346.
- 26 Hederman WP: Endoscopic sympathectomy. *Br J Surg* 1993;80:687–688.
- 27 Sung SW, Kim YT, Kim JH: Ultra-thin needle thoracoscopic surgery for hyperhidrosis with excellent cosmetic effects. *Eur J Cardiothorac Surg* 2000;17:691–696.